


# Evaluation of a Nitinol Frame Containing Device (Rebound HRD) for Minimal Access Transinguinal Preperitoneal Groin Hernia Repair



Frederik Berrevoet, MD  
*Department of General and Hepatobiliary Surgery and Liver Transplantation Service  
University Hospital Ghent, Belgium*

### Summary

To improve patient outcome and minimize pain post-surgery after inguinal hernia repair, a small incision, limited dissection around the cord and the nervous structures and no necessity for fixation of the reinforcing mesh are possible issues that could achieve this.

We evaluated a new lightweight macroporous device with a continuous Nitinol frame to facilitate mesh introduction in the preperitoneal pocket that was created by only minimal open surgical access. While we as surgeons were extremely satisfied with the easy placement and the final flat positioning of the device, especially at the lateral side, our patients seemed very satisfied with both the cosmesis and the results concerning pain and convalescence.

### Introduction

The increasing number of reports with high incidences of postoperative pain after open anterior mesh repair need consideration. In theory, 5 issues need to be addressed when evaluating possible etiologies for pain after inguinal hernia repair: small incision, minimal dissection around the inguinal nerves, location of the mesh in the preperitoneal space, being more towards the human physiology, and not in contact with the nerves, minimal fixation of the mesh and no extensive amount of material to prevent severe local inflammation and fibrosis around the nerves and the cord structures during tissue ingrowth.

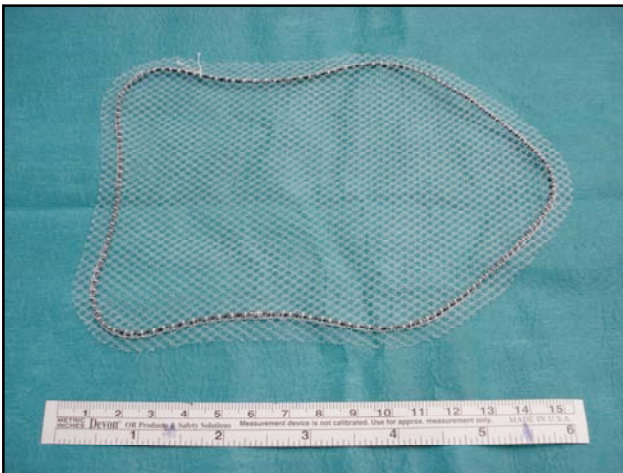
We evaluated a new type of hernia repair device, the Rebound HRD, made from a lightweight polypropylene and a Nitinol frame to facilitate

---

preperitoneal placement through a minimal surgical incision.

## Materials and methods

All patients studied had a diagnosis of primary uni- or bilateral inguinal or femoral hernia. We utilized a self-expanding hernia repair device that consists of a macroporous polypropylene mesh with a continuous Nitinol frame producing a certain tension on the outer border of the mesh that keeps the mesh flat and allows for easy deployment of the mesh in the created preperitoneal pocket.

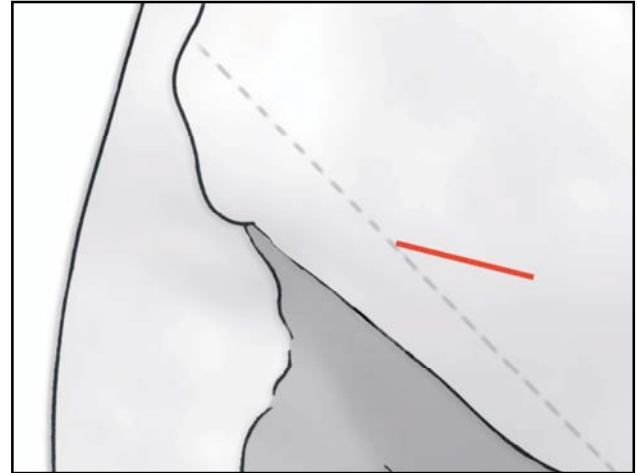


*The Rebound HRD Large Shield device approximately 16.2 x 11.2cm.*

### *Open minimal invasive preperitoneal groin hernia repair – surgical technique*

A 3cm skin incision is performed under spinal or general anaesthesia, depending on the patients' preference. The incision starts half way the line between the superior anterior iliac spine towards

the midline in a 30 ° angle to the pubic tubercle.



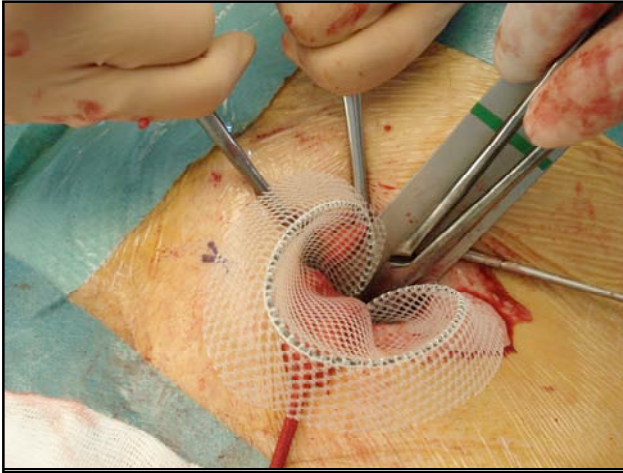
*Skin incision preoperatively for unilateral groin hernia repair.*

Scarpa's fascia is opened as well as the external oblique aponeurosis. By using this skin line incision the internal ring will be immediately visualized. The lateral or medial sac is dissected and reduced or resected according to the preference of the surgeon with minimal dissection around the cremaster muscle and the nerves. The preperitoneal space is entered bluntly through the internal ring. As primary point of concern the epigastric vessels should be identified and retracted softly upwards. Then a gauze is introduced into the preperitoneal space and by doing so most of the space needed medially will be created. Laterally to the internal ring more digital dissection is needed to create just the appropriate space for the device. We introduce a malleable retractor into the preperitoneal pocket and then introduce the Rebound HRD large shield device of 16.2 x 11.2cm using the retractor as a slide. Using two (2) forceps the device is easily introduced behind the pubic tuber-

---

---

cle with 2-3cm overlap to prevent medial recurrences. Thereafter, the device is grasped with the two (2) forceps a few centimeters from the lateral edge and this part of the device is then put in the lateral pocket.



*Preperitoneal dissection and positioning of the malleable retractor as a slide for the device introduction.*

The strong memory frame of the device deploys the mesh completely in the created pocket without the need for any fixation. Splitting of the mesh to create a new internal orifice is not necessary. The patient will be asked to strain and push on the Nitinol frame to control its position and to check adequate spreading of the mesh to cover the whole myopectineum of Fruchaud. Local long-acting anaesthetic is then injected around the cord, intramuscularly and cutaneously. No local anaesthetics are injected in the preperitoneal space to avoid temporary paralysis of the M.Quadriceps femoris, leading to inability of the patient to lean on the operated leg for the next 4 -6 hours after the operation. Subcutaneous tissue and skin are closed with absorbable sutures.

## Results

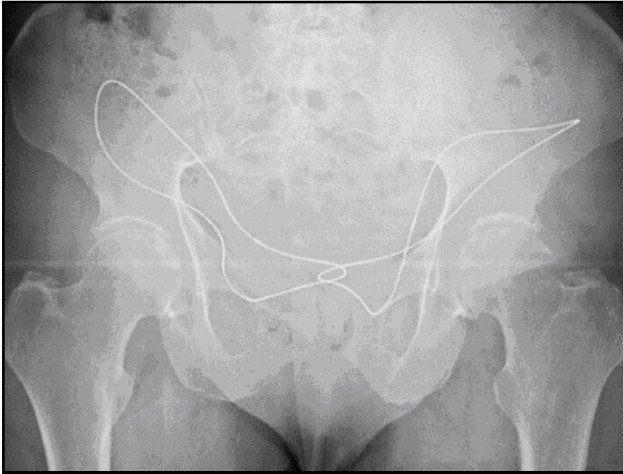
The use of this device was evaluated during open preperitoneal hernia repair for uni- and bilateral groin hernias. When using a small inguinal incision of 3cm to improve cosmesis, it is efficient and easy to use this self-expandable Rebound HRD device with a memory frame that helps the surgeon with both medial and lateral positioning of the device. It facilitates placement for the surgeon and eliminates the need for extensive dissection and fixation of the device in the preperitoneal space, reducing postoperative pain for the patient. Performing the same minimal access technique using a normal flat mesh, either micro- or macroporous, is almost impossible or extremely troublesome to say the least. With this minimal access incision the cosmetic result is excellent, certainly compared to other, more classical, types of open repair like the Lichtenstein repair or the plug and patch technique.

We experienced this device in only 10 patients, but the use of this device resulted in a very elegant and quick placement of the device with a mean operative time of 26 minutes. When this technique is compared to using a device without the Nitinol frame, e.g. using an interrupted polyester ring, a mean time saving of 7 minutes can be observed. No signs of postoperative seroma, superficial nor deep (mesh) infections were observed and there was no need for surgical reintervention in any patient. Radiological X-ray showed efficient coverage of the inguinal and femoral canal in all patients

---

---

with excellent deployment of the complete Nitinol frame and polypropylene mesh.



*Radiological imaging confirms positioning, post-surgery, after bilateral groin hernia repair.*

The observed short-term patient comfort was excellent with low pain scores using the visual analogue scale and with a rapid reconvalescence within 7 days. Further clinical experience is necessary to evaluate the long-term follow-up and the future behavior of the Nitinol frame.

## **Conclusions**

During recent years the discussion about inguinal hernia repair more and more focuses on chronic pain and quality of life, rather than the percentages of recurrence. Chronic pain seems to involve up to 40% of patients after different types of groin hernia repair. This minimal invasive preperitoneal technique using a macroporous mesh with internal Nitinol frame, the Rebound HRD Large Shield device, offers several advantages compared with traditional anterior approaches. There is no need for extensive dissection around the cord limiting

the potential lesions of the inguinal nerve structures, the device lies flat in the preperitoneal space, in which no scar tissue will implicate the nerves after surgery and the strong memory of the Nitinol frame ensures a very effective deployment of the device once the pocket is created without the need for extensive suturing or the use of expensive fixation devices. Our patients expressed a high level of satisfaction and radiological imaging showed an efficient treatment of the hernia in all patients.

Our initial experience with the Nitinol frame containing Rebound HRD Large Shield device gives excellent surgeon's handling and is very easy to use, while patients experience a high level of satisfaction and a rapid reconvalescence after surgery.

*This whitepaper was published, with thanks to Frederik Berrevoet, MD, by Minnesota Medical Development, Inc. (MMDI), Plymouth, MN.*

*For more information on the Rebound HRD please contact MMDI at 763-354-7100 or [www.2mdinc.com](http://www.2mdinc.com).*

---